

NEW SURGICAL TECHNIQUE FOR SPHINCTER URINARY CONTROL SYSTEM USING UPPER TRANSVERSE SCROTAL INCISION

STEVEN K. WILSON,*† JOHN R. DELK, II,‡ GERARD D. HENRY† AND ANDREW L. SIEGEL

From the Institute for Urologic Excellence, Van Buren, Arkansas, and the Department of Urology, Hackensack University Medical Center, Hackensack, New Jersey

ABSTRACT

Purpose: Traditional implantation of the AMS Sphincter 800 Urinary Control System (American Medical Systems, Minnetonka, Minnesota) requires 2 incisions. The cuff is placed via a perineal incision, and the pressure regulating balloon and pump are placed through a separate suprapubic incision. We describe a novel implantation of all the artificial urinary sphincter components using a single upper scrotal incision. The scrotal incision allows excellent access to the proximal bulbar urethra and retropubic and subdartos spaces, and leaves the bulbocavernosus muscle intact.

Materials and Methods: A total of 37 patients have undergone artificial urinary sphincter implantation using the new operative technique for revisions or reimplantations of a sphincter previously removed for infection/erosion (12) or as an initial procedure (25). In 9 of the 25 patients and 2 of the 12 dual implantation of a 3-piece penile prosthesis through the same incision was performed.

Results: All patients are using the devices. Of the patients 66% are completely dry with no pad use and the remainder use 1 pad for accident prevention. Operative time was reduced due to easier exposure of the urethra and a second incision for placement of the pressure regulating balloon was not necessary. Followup at 1 year shows no difference in complication rate with the single incision technique compared to the traditional method.

Conclusions: Artificial urinary sphincter implantation through a single scrotal incision is easier and faster than the traditional 2-incision technique. Success in achieving continence is similar to traditional methods. Long-term followup is necessary to ensure that complications remain low.

KEY WORDS: urethra, urinary sphincter, artificial; urinary incontinence

Placement of an artificial urinary sphincter via a scrotal approach is a natural extension of the penoscrotal technique for implantation of an inflatable penile prosthesis. Using an upper transverse scrotal incision, rapid access to the proximal bulbar urethra can be achieved by exposing the proximal corpora as for penile prosthesis surgery. The location of the occlusive cuff around the urethra as it emerges from the diverging corpora is the same location as that achieved by the traditional perineal approach. The pressure regulating balloon is placed in the retropubic space in a manner similar to the way the reservoir for the 3-piece penile implant is placed. A subdartos pouch within the scrotum is created to house the control pump.¹ We analyzed early results with this new transscrotal approach.

METHODS AND MATERIAL

All components of the AMS Sphincter 800 Urinary Control System were placed via a transverse scrotal incision in 37 patients. Initially the technique was used for revisions in 5 cases, reinsertions of sphincters previously removed for infection in 5 and addition of second cuffs to existing sphincter systems in 2. Three revisions were done for urethral atrophy underneath cuffs that had previously been placed via a perineal incision several years earlier. This experience with revisions and replacements convinced us that using a scrotal

incision, it was possible to place the sphincter cuff in the identical deep bulbar location as with a perineal incision. We began placing sphincters in patients with no history of sphincter surgery 3 years ago and have followed 25 patients for at least 1 year. Of these previously unoperated patients 9 had a 3-piece penile prosthesis implanted concomitantly through the same incision. Of the revision group 2 underwent simultaneous penile prosthesis placement.

Etiology for incontinence was radical prostatectomy in 30 patients, transurethral resection of the prostate in 2 and radical prostatectomy plus radiation therapy in 5. Five patients had undergone previous transurethral incision of the bladder neck for contracture secondary to radical prostatectomy, and in 2 a UroLume (American Medical Systems, Minnetonka, Minnesota) had been placed 3 months previously for intractable bladder neck stricture secondary to radical prostatectomy. Cuff size was 4.0 cm. in 32 patients and 4.5 cm. in 5. Pressure regulating balloons were 61 to 70 cm. H₂O in 32 patients and 51 to 60 cm. H₂O in 5 who had undergone radiation therapy.

SURGICAL TECHNIQUE

After shaving and administration of broad-spectrum intravenous antibiotics, the patient is placed supine (not in stirrups) with the legs gently abducted, and the genitalia are scrubbed for 10 minutes with povidone-iodine soap. The patient is prepared with povidone-iodine solution and draped for a scrotal incision. A urethral catheter is placed to drain the bladder to avoid injury during placement of the pressure regulating balloon. The catheter also facilitates urethral dissection.

Accepted for publication July 5, 2002.

* Requests for reprints: 2010 Chestnut St., Van Buren, Arkansas, 72956.

† Financial interest and/or other relationship with American Medical Systems and Mentor.

‡ Financial interest and/or other relationship with American Medical Systems.

Use of the Scott retractor and 2 infant Deavers will facilitate transscrotal placement of artificial urinary sphincter. Alternately, a curved cerebellar self-retaining retractor may be used. An upper transverse scrotal incision is made and deepened through the subcutaneous tissue (fig. 1). The incision is moved onto the penis and stabilized with blunt stay hooks at 1,3,5,7,9 and 11 o'clock positions. These stay hooks secure the scrotal incision onto the penis and help prevent unnecessary dissection in the scrotum. The stays are repositioned as deeper layers of tissue are dissected.

The tunica albuginea of both corpora cavernosa are exposed sharply. Metzenbaum scissors are passed proximally along the ventral surface of the tunica to the proximal corpora. When deep exposure of the proximal corpora is secured, infant Deaver retractors are placed on both sides of the urethra for caudad traction. With caudad traction of the 2 retractors by the surgical assistant, the surgeon can then sharply dissect the scrotal septum off the bulbar urethra (fig. 2, A). The key to proper urethral exposure is to first expose the corpora proximally and then divide the scrotal septum (fig. 2, B). By sharply dissecting webs of Buck's fascia binding the diverging corpora cavernosa to the corpora spongiosa, mobilization of the urethra can be readily achieved. Because the approach is from above rather than through the perineum, the bulbocavernosus muscle is not a factor.

With the patient supine the urethra is mobile as opposed to being on stretch as it is in the lithotomy position. Posterior

urethral dissection is facilitated since it is done under direct vision rather than blindly as in the perineal approach. The urethral circumference is measured using the cuff sizer. The measurement has been 4.0 cm. in the majority of implants. The occlusive cuff evacuated of air is then placed around the urethra in standard fashion (fig. 2, C). An absorbable suture is used to close the dartos over the cuff.

After ensuring that the bladder is empty, the scrotal incision is displaced to the side of the penis. The pressure regulating balloon is placed in a fashion similar to placing a penile implant reservoir. The transversalis fascia is pierced immediately above the pubic bone and the pressure regulating balloon is placed within the retropubic space (fig. 3). We usually do not close the opening into the retropubic space. If difficulty is encountered piercing the scarred transversalis fascia, the pressure regulating balloon may be placed in the epigastric area superior to the transversalis fascia by finger dissecting a space cephalad to the external ring. The balloon is filled with 22 to 25 cc of saline.

The inferior aspect of the scrotal incision is elevated, and a space underneath the scrotal skin and dartos muscle is developed to serve as a pouch for the pump. The pump is positioned within this space so that it sits in an easily palpable, dependent scrotal position (fig. 4). A purse-string suture around the opening of the tunnel is loosely tied to secure the pump position. The components are connected and the device is tested. Absorbable suture is used to close the dartos and scrotal skin. The pump is deactivated in the usual way. A drain is not commonly used. The Foley catheter is removed when the patient has recovered from anesthesia. The patient is sent home on a same day basis or observed overnight. The sphincter is activated in 6 weeks.

RESULTS

At followup of 6 to 30 months (mean 12) all patients are using the sphincters. Of the patients 25 are dry and do not use pads, while 12 usually wear 1 pad as a precaution for accidents. No patient uses more than 1 pad a day. In 1 case of a previous penile implant iatrogenic laceration of the urethra occurred and the procedure was aborted. Early (3 and 6 weeks) cuff erosion before device activation occurred in 2 cases of reimplantation for sphincters previously removed for erosion/infection. Subsequent artificial urinary sphincter placement was successful in all 3 cases. We reimplanted 2 sphincters using the transscrotal incision and 1 case was treated elsewhere with the traditional perineal approach. One patient with dual implantation had early penile prosthesis infection. The penile prosthesis was removed and the sphincter remains uninfected. The penile implant was replaced 6 months later without disturbing the sphincter.

Operative time for artificial urinary sphincter placement was less than 1 hour in all cases. Average operative time was 35 minutes (range 20 to 52) in the 25 initial cases. If simultaneous 3-piece penile prosthesis placement was done in patients with no previous surgery operative time averaged 59 minutes (range 50 to 95). No patient reported sensations of discomfort from the scrotally placed cuff. No patient to date has reported leakage from cuff compression, late cuff erosion or return of incontinence (urethral atrophy or mechanical failure).

DISCUSSION

The AMS 800 Sphincter Urinary Control System has been effective in managing male urinary incontinence since 1972, with early success rates of up to 90% in large series.² Gousse et al reported that 77% of patients followed up to 7 years were very satisfied (58%) or satisfied (19%) with results of the procedure.³ Despite this enviable outcome it is estimated that only 2,500 artificial urinary sphincter procedures are done yearly in the United States. It is also estimated that

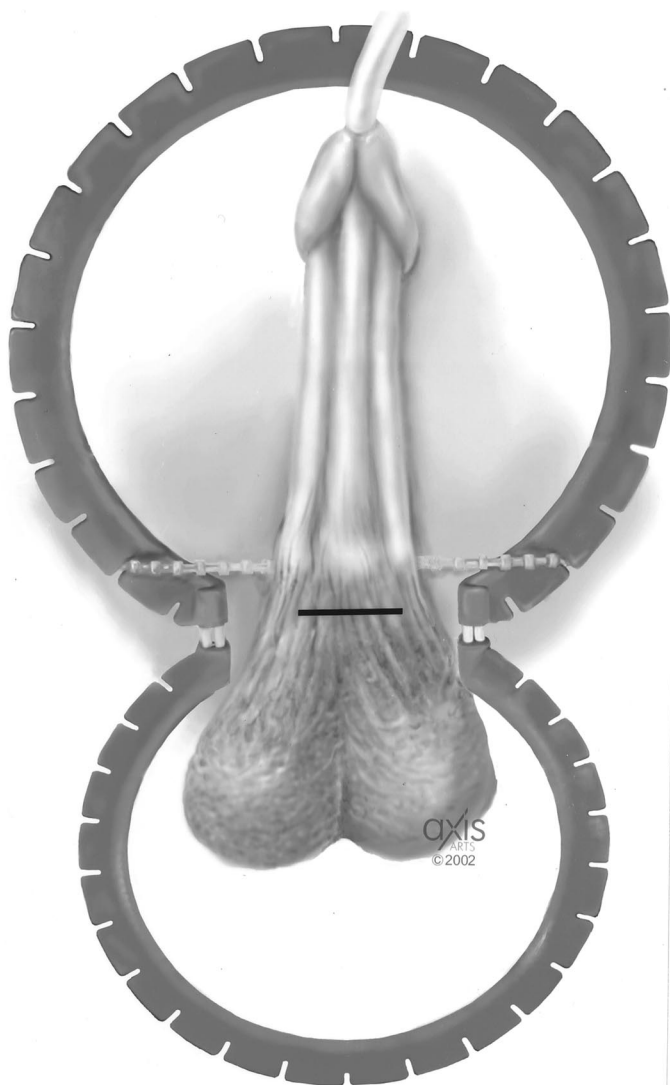


FIG. 1. Upper transverse scrotal incision

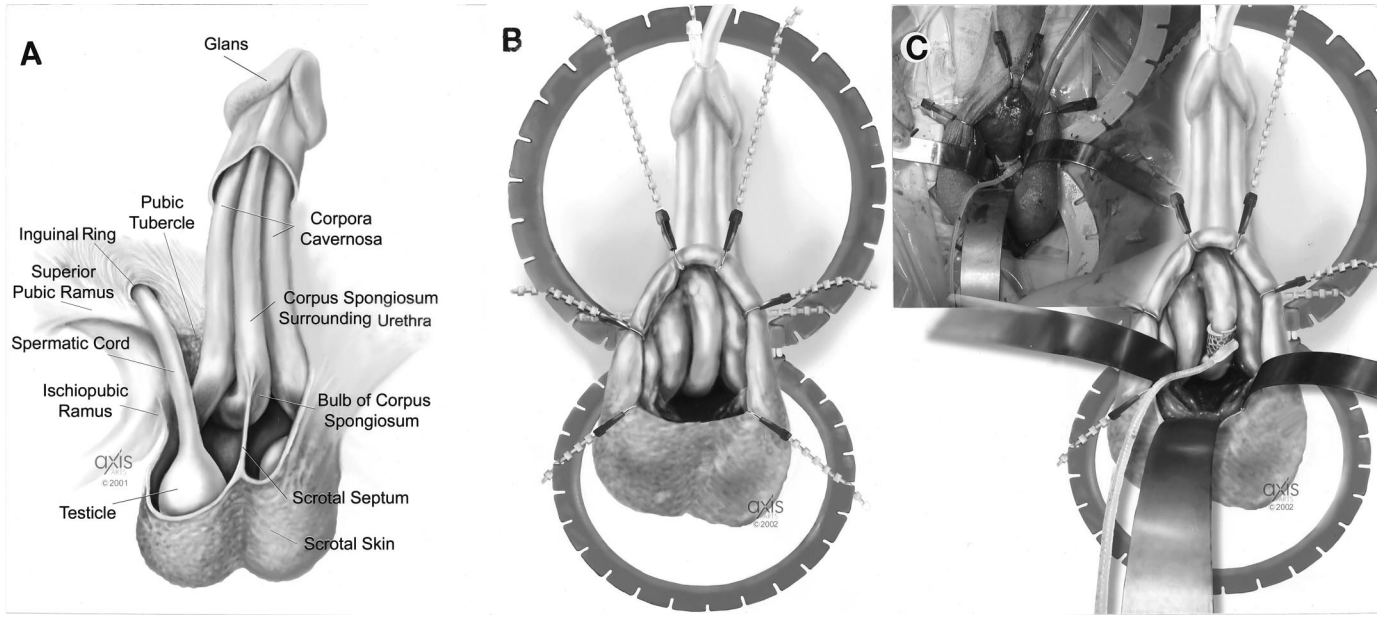


FIG. 2. A, anatomy of scrotal exposure of proximal urethra. B, exposure of proximal corpora and division of septum reveal proximal bulbar urethra. C, cuff placed where corpora decussate.

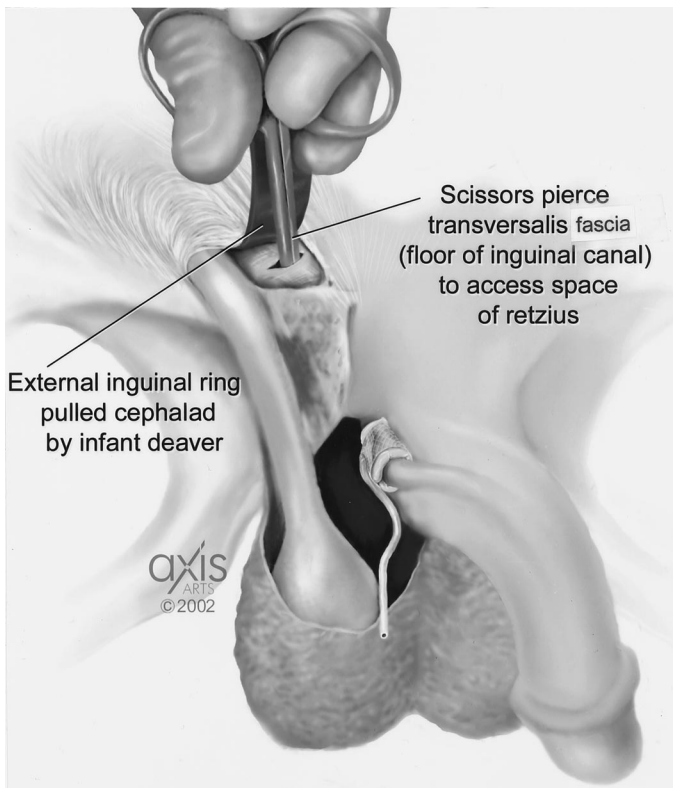


FIG. 3. Pierce transversalis fascia to place pressure regulating balloon.

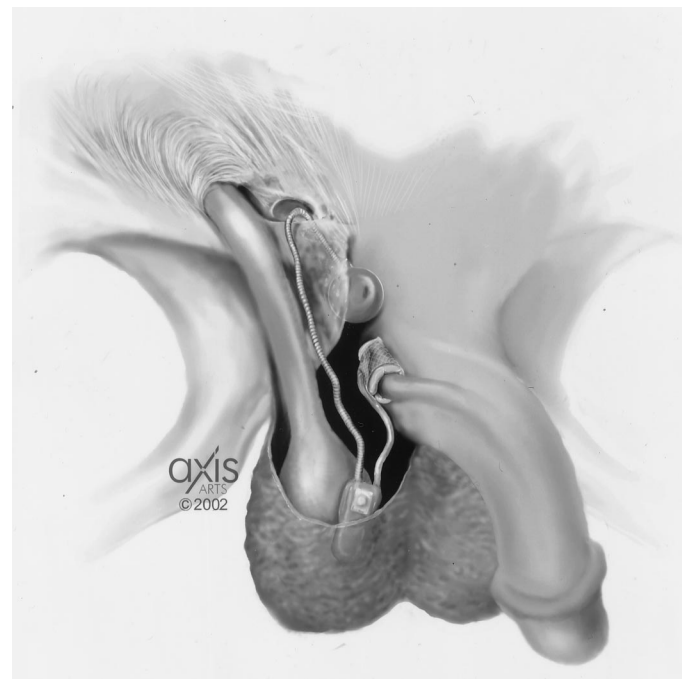


FIG. 4. Pump placed in subdartos pouch

only 15% of American urologists perform this surgery in a given year (statistics from American Medical Systems). Perhaps these small numbers reflect surgeon discomfort with the traditional technique.

The technique of dual incision artificial urinary sphincter placement has not changed in 30 years and has some drawbacks. Making 2 incisions is time-consuming. Urethral exposure through a perineal incision is tedious because the posterior dissection is largely blind. Another disadvantage of the traditional method is that pump placement may be subopti-

mal since the pump is maneuvered into the scrotum via the abdominal incision and may subsequently retract into the inguinal region.

The new high scrotal, 1-incision approach is particularly useful for revision surgery. The most common reason for revision is recurrent incontinence, usually due to urethral atrophy under the cuff.⁴ Using 1 incision the old cuff is easily removed and a new cuff placed 1 to 2 cm. distal to the old urethral location. Alternatively, the old cuff is left in place and a cuff is added in tandem to the system using a Y connector.⁵

Erosion of the cuff occurs in approximately 5% of sphincter cases, and it may be iatrogenic or due to infection.² Our 2 complications occurred early in the clinical course and are believed to be iatrogenic. In both cases the patients had had

previous sphincters placed through a perineal incision. Both early erosions and the urethral laceration occurred early in the development of this transscrotal approach. The area of urethral dissection was distal to where the corpora decussate because that deep bulbar location was scarred from the previous cuff. The urethra was adherent to the corpora cavernosa. Guralnick et al used transcorporeal dissection leaving corporeal tunica albuginea on the dorsal surface of the urethra to obviate this difficult dissection.⁶ We have since used their technique with success, and there have been no late erosions or infections in the short followup.

The scrotal incision allows excellent access to the proximal bulbar urethra and retropubic and subdartos spaces, and leaves the bulbocavernosus muscle intact. While this technique initially was developed for revision and reimplantation surgery, the transscrotal approach is now used for sphincter cases in patients who have not previously undergone sphincter surgery. Our experience with cuff position during revision surgery on existing cuffs that had been placed through a traditional perineal incision has convinced us that the cuff can be placed in the similar proximal bulbar location using an upper scrotal incision. In other words, we could place the cuff as deep on the proximal bulbar urethra coming from above through the scrotum, as we could coming from below through the perineum.

The transscrotal technique affords some advantages over the dual incision approach. Because this technique requires only 1 incision, implantation can be performed faster than the standard 2-incision approach. The scrotal incision technique is performed with the patient supine. Because the patient is not in the lithotomy position, the urethra is more mobile and this mobility facilitates posterior dissection. Initially the scrotal approach was done with the patient in stirrups but it was found that the posterior urethral dissection was troublesome. Placement of the legs in stirrups puts the urethra on stretch.

Displacement of the scrotal incision over the inguinal area allows the surgeon to place the pressure regulating balloon in an identical fashion as placement of the reservoir in 3-piece penile implants. If the transversalis fascia is excessively scarred, the balloon can be placed underneath the rectus muscle but superior to the transversalis fascia. We used this ectopic placement in 3 patients. While reservoir hernia develops in less than 1% of penile implants,⁷ it has not occurred to date in our sphincter implants.

Placement of the sphincter pump from the abdominal incision into the scrotum has always been problematic. If edema or hematoma of the scrotum occurred, the pump occasionally retracted into the upper groin making use by the patient difficult. Because the pump is placed virtually under direct vision with the transscrotal approach and the ostium of its tunnel is closed with a purse-string suture, there were no malpositioned or high riding pumps in our series.

Our followup is short and a proportion of our patients will undoubtedly require surgical revision to maintain continence in the future. The need for any revision is high in patients treated with an artificial urinary sphincter.⁸ Venn et al reported a 60% 5-year survival without reoperation for bulbar urethral sphincter placement but did not consider early operative revision for iatrogenic problems in the calculation and, thus, greatly overestimated freedom from revision for any cause.⁹ Clemens et al reported an actuarial analysis of

the revision rate for 70 consecutive patients undergoing artificial urinary sphincter placement, and the 5-year actuarial rate for freedom from any operative revision was 50%.¹⁰ There were 15 reoperations in the first year with cuff revisions accounting for 11% in their series.

Erosions in the first year after device implantation almost always occur because of injury to the bulbous urethra during mobilization.¹¹ At 1-year followup there were 3 episodes of urethral injury (8%) in our previously operated patients. Most authorities acknowledge that complications necessitating device revision and/or explantation may appear years after a successful implantation.^{3,12} Since this new technique is being presented to augment or replace a surgical technique used for 30 years, we realize that long-term followup and a larger series will be required to assess whether the revision rate remains acceptable.

CONCLUSIONS

The high transverse scrotal incision allows excellent access to the proximal bulbar urethra, and retropubic and subdartos spaces, permitting implantation of all 3 components through a single incision. Transscrotal implantation of the AMS Sphincter 800 Urinary Control System using only 1 incision offers significant advantages over the traditional 2-incision method for sphincter revisions and reimplantations of sphincters previously removed for infection/erosion. Early results also show an advantage in patients without previous sphincter surgery. The surgery in both groups is easier and quicker. The continence results are similar for both methods. Long-term followup and more implantations are needed to determine if the complication rate remains acceptable.

REFERENCES

1. Wilson, S. K. and Delk, J. R.: A new approach for implantation of artificial urinary sphincter: upper transverse scrotal incision. *J Urol*, suppl., **165**: 256, abstract 1053, 2001
2. Montague, D. K. and Angermeier, K. W.: Postprostatectomy urinary incontinence: the case for artificial urinary sphincter implantation. *Urology*, **55**: 2, 2000
3. Gousse, A. E., Madjar, S., Lambert, M.-M. and Fishman, I. J.: Artificial urinary sphincter for post-radical prostatectomy urinary incontinence: long-term subjective results. *J Urol*, **166**: 1755, 2001
4. Fishman, I. J., Shabsigh, R. and Scott, F. B.: Experience with the artificial urinary sphincter model AS800 in 148 patients. *J Urol*, **141**: 307, 1989
5. Brito, C. G., Mulcahy, J. J., Mitchell, M. E. and Adams, M. C.: Use of a double cuff AMS800 urinary sphincter for severe stress incontinence. *J Urol*, **149**: 283, 1993
6. Guralnick, M. L., Miller, E., Toh, K. L. and Webster, G. D.: Transcorporeal artificial urinary sphincter cuff placement in cases requiring revision for erosion and urethral atrophy. *J Urol*, **167**: 2075, 2002
7. Sadeghi-Nejad, H., Sharma, A., Irwin, R. J., Wilson, S. K. and Delk, J. R.: Reservoir herniation as a complication of three-piece penile prosthesis insertion. *Urology*, **57**: 142, 2001
8. Stone, N. N.: Editorial comment. *J Urol*, **166**: 1375, 2001
9. Venn, S. N., Greenwell, T. J. and Mundy, A. R.: The long-term outcome of artificial urinary sphincters. *J Urol*, **164**: 702, 2000
10. Clemens, J. Q., Schuster, T. G., Konnak, J. W., McGuire, E. J. and Faerber, G. J.: Revision rate after artificial urinary sphincter implantation for incontinence after radical prostatectomy: actuarial analysis. *J Urol*, **166**: 1372, 2001
11. Montague, D. K.: Editorial comment. *J Urol*, **166**: 1375, 2001
12. Diokno, A. C.: Editorial comment. *J Urol*, **164**: 706, 2000