

FEMALE PELVIC RELAXATION



A Primer for Women with Pelvic Organ Prolapse

Written by:

ANDREW SIEGEL, M.D.

An educational service provided by:

**BERGEN UROLOGICAL ASSOCIATES
N.J. CENTER FOR PROSTATE CANCER & UROLOGY**

ANDREW SIEGEL, M.D. • MARTIN GOLDSTEIN, M.D.
VINCENT LANTERI, M.D. • MICHAEL ESPOSITO, M.D. • MUTAHAR AHMED, M.D.
GREGORY LOVALLO, M.D. • THOMAS CHRISTIANO, M.D.

255 SPRING VALLEY AVENUE
MAYWOOD, N.J. 07607

WWW.BERGENUROLOGICAL.COM
WWW.ROBOTICUROLOGY.COM

Table of Contents

INTRODUCTION	1
WHY A UROLOGIST?	2
PELVIC ANATOMY	4
PROLAPSE	
URETHRA	7
BLADDER.....	7
RECTUM.....	8
PERINEUM	9
SMALL INTESTINE	9
VAGINAL VAULT.....	10
UTERUS	11
EVALUATION OF PROLAPSE.....	11
SURGICAL REPAIR OF PELVIC PROLAPSE	15
STRESS INCONTINENCE.....	16
CYSTOCELE	18
RECTOCELE/PERINEAL LAXITY.....	19
ENTEROCELE AND VAULT PROLAPSE	20
UTERINE PROLAPSE	21

Introduction

Pelvic relaxation is a common condition in which there is weakness of the supporting structures of the female pelvis, allowing descent (prolapse) of one or more of the pelvic organs through the “potential space” of the vagina. These organs include the following: urethra, bladder, rectum, small intestine, uterus, and the vagina (vaginal vault) itself. The urethra and bladder are anatomically situated above the “roof” or top wall of the vagina, the cervix and uterus at the very deepest part of the vagina (the apex), and the rectum below the “floor” or bottom wall of the vagina. Thus, when prolapse develops, one or more of the following may occur: the urethra and bladder may descend into the vaginal roof, the cervix and uterus may descend into the vaginal canal, and the rectum may ascend into the vaginal floor. Pelvic relaxation can vary from minimal descent—causing few, if any, symptoms—to major descent—in which one or more of the pelvic organs literally prolapse outside the vagina at all times and cause significant symptoms. The degree of descent often varies with position and activity level, increasing with the upright position and with exertional activities, and decreasing with lying down and resting.

Pelvic relaxation usually results from a combination of factors including multiple pregnancies and vaginal deliveries (especially deliveries of large babies), menopause, hysterectomy, aging, weight gain, and any condition associated with chronic increases in abdominal pressure, such as asthma and bronchitis (chronic wheezing and coughing), seasonal allergies (chronic sneezing), or constipation (chronic straining). Vaginal birth is the single most important factor in the development of prolapse. Passage of the large human head through the female pelvis causes tissue trauma, separation or weakness of connective tissue attachments, and alterations in the geometry of the pelvis. It is unusual for women who have not had children or who have delivered by elective caesarian section to develop significant pelvic relaxation.

Because the female genital tract and urinary tract are intimately related (due to their anatomic proximity as well as a common embryological origin), pelvic relaxation can cause significant changes in normal urinary function. These range from stress urinary incontinence (a spurt-like leakage of urine from the urethra associated with an increase in abdominal pressure such as occurs with sneezing, coughing, etc.), to

an inability to empty the bladder unless one manually pushes back the prolapsed bladder. It is important to know that such symptomatic pelvic relaxation can be corrected. The goal of pelvic reconstructive surgery is to restore normal anatomy and function. Non-operative treatment of pelvic relaxation is used when symptoms are minimal or when surgery cannot be performed because of infirmity and frailty. Such conservative treatment options include change of activities, management of constipation and other circumstances that increase abdominal pressure, pelvic floor exercises, hormone replacement, and pessaries. Pessaries are mechanical devices that are inserted into the vagina to act as “struts” to help provide pelvic support. The side effects of pessaries are vaginitis (vaginal infection and discharge), extrusion (the inability to retain the pessary in proper position), and the “unmasking” of stress incontinence.

Why a Urologist?

You may wonder why a urologist is interested in female pelvic relaxation, since for many years urology was traditionally considered to be a male field. In the late 1970's, female urology emerged as a specialty branch of urology much as pediatric urology had done previously. The person largely responsible for this emergence was Dr. Shlomo Raz, director of female urology at the U.C.L.A. School of Medicine. Dr. Raz, a world-renowned physician and surgeon, developed the field of female urology into a comprehensive surgical discipline. In addition to writing the textbook *Atlas of Transvaginal Surgery* and editing the textbook *Female Urology*, Dr. Raz is responsible for redefining the previously confusing nomenclature of female pelvic anatomy. For the past four decades, Dr. Raz has hosted a fellowship at U.C.L.A. in which two surgeons per year are trained with him in all aspects of female urology. I was fortunate to be selected for one of these positions and after the completion of my urology residency at the University of Pennsylvania School of Medicine, spent one year operating with Dr. Raz, focusing on prolapse, incontinence, and voiding dysfunction. Obviously, prolapse is an exclusively female field, but incontinence and voiding dysfunction encompass both females and males. My practice is, in fact, almost equally divided between women and men, and I find that I enjoy this balance.

For years, the urologist's role in female pelvic relaxation was limited to surgery for urinary incontinence, and other aspects of pelvic relaxation were largely ignored. Similarly, the gynecologist's role in female pelvic relaxation was focused on prolapse of the bladder, uterus, and rectum, but ignored the urethral prolapse that is often responsible for stress urinary incontinence. Thus there was a division of labor, a "territoriality" within the realm of female pelvic surgery, as illustrated

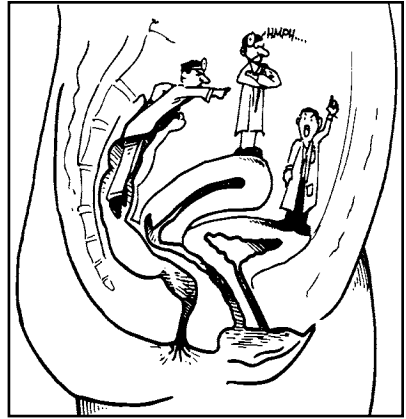


Figure 1

in this cartoon demonstrating the roles of the urologist, gynecologist, as well as the colon/rectal surgeon. (Figure 1). Dr. Raz espoused the concept of a pelvic surgeon, one capable of dealing with any and all aspects of female pelvic relaxation, with a thorough knowledge of pelvic anatomy and plastic surgical reconstructive principles. The ultimate goal of the female urology fellowship that Dr. Raz established became to train accomplished pelvic surgeons who could then obtain academic positions at University medical centers throughout the United States, the appropriate venue for further dissemination of the art and science of female urology and pelvic reconstructive surgery to medical students and residents in training. Thus, at Hackensack University Medical Center, one of my roles is to instruct urology residents and medical students from the Rutgers New Jersey Medical School in the principles and surgical techniques of Dr. Raz.

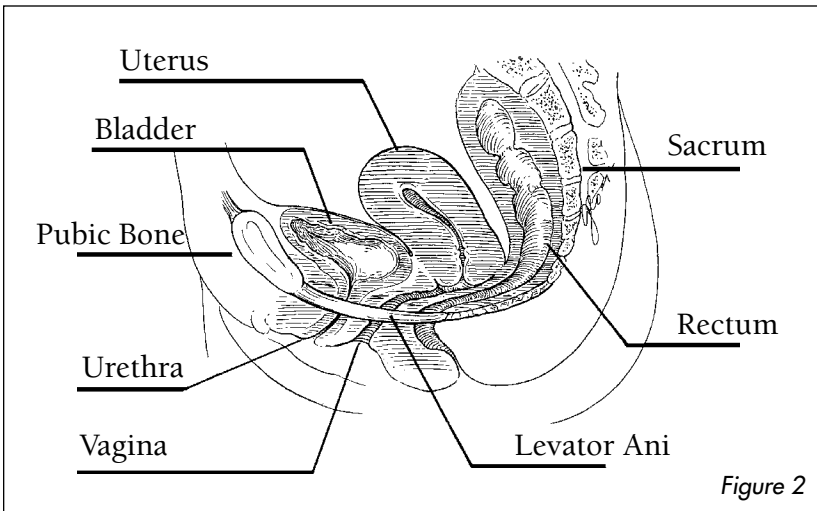
Female pelvic reconstructive surgery incorporates principles of both urological, gynecological, and plastic surgery. A pelvic reconstruction for pelvic prolapse is not dissimilar to cosmetic facial surgical procedures performed by plastic surgeons for aging and sagging eyelids and jowels. Both pelvic reconstructive and plastic facial reconstructive surgery require some degree of creativity and artistic talent in addition to the scientific knowledge of anatomy and surgical principles. I personally find female reconstructive surgery to be particularly gratifying because of both the instant ability to assess the results before leaving the operating room as well as the great potential to improve the lifestyle and function of the person suffering with prolapse. Unlike facial cosmetic surgery, pelvic reconstruction, in addition to improving

cosmetic appearance, aims for functional improvement in terms of of incontinence, voiding dysfunction, sexual dysfunction, bowel dysfunction, and other symptoms associated with pelvic prolapse.

Anatomy of The Female Pelvis

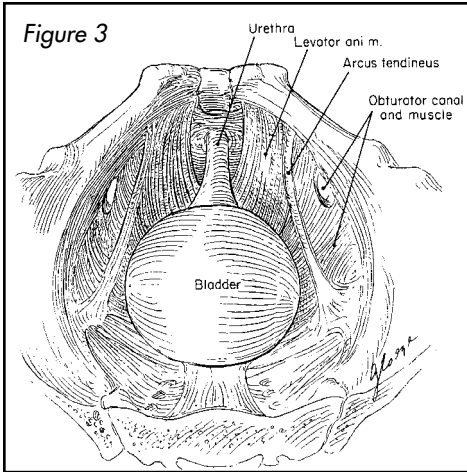
A basic knowledge of pelvic anatomy will allow you to understand why prolapse occurs and how it can be corrected. (Figure 2).

The bony pelvis is the framework to which the support structures of the pelvis are attached. The pelvis is defined as the cup-shaped



ring of bone at the lower end of the trunk, formed by the hip bone (comprised of the pubic bone, ilium, and ischium) on either side and in front, and the sacrum and coccyx in back. Located within this “scaffolding” are the urinary structures (bladder, urethra), genital structures (vagina, cervix, uterus, fallopian tubes, ovaries), and the rectum.

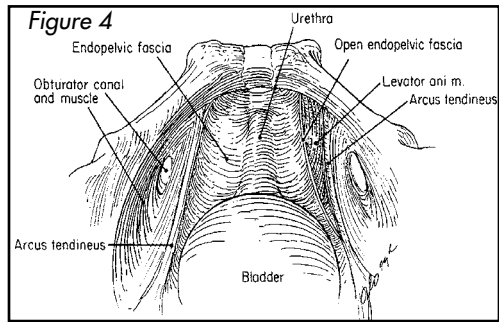
The failure of the pelvic support system allows for descent of one or more of the pelvic organs into the potential space of the vagina, and at its most severe degree, outside the vaginal opening.



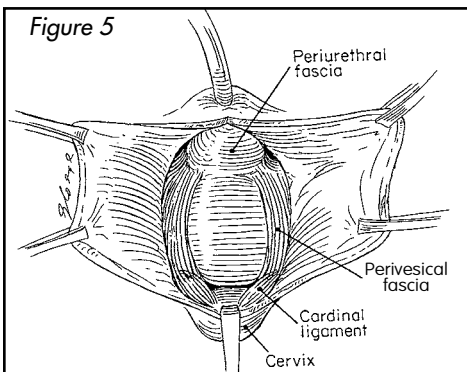
Abdominal View of The Bladder

creating a hammock-like structure. This levator “hammock” has openings through which the vagina, rectum, and urethra traverse.

There are several *fascias* that are important in providing pelvic support. Fascia is the tough, fibrous tissue that envelopes muscles. The *levator fascia* covers both sides of the levator ani muscle. The “pelvic leaf” fuses with the “vaginal leaf” to insert into the tendinous arc. The pelvic leaf is called the *endopelvic fascia*. (Figure 4).



Endopelvic Fascia Overlying Levators



Vaginal View of Bladder Support

The levator ani muscle is the major muscle that provides support to the urethra, vagina, and rectum. (Figure 3). The levator ani arises from the pubic bone, the ischial spine, and the tendinous arc. The *tendinous arc* is a very important anatomic support in the pelvis because it forms the common insertion point for a set of pelvic muscles including the levator ani muscles. The levator ani muscle extends from the left tendinous arc to the right tendinous arc,

The vaginal leaf is called the *perivaginal fascia* (at the level of the urethra), and the *perivesical fascia* (at the level of the bladder). (Figure 5). Contained within the two leaves of the levator fascia are the pelvic organs to which it provides support: the urethra, bladder, vagina, and uterus.

Specialized regions of the levator fascia form critical

ligamentary supports to maintain the relationships between the urethra, bladder, vagina, and uterus within the bony pelvis. These specialized regions are the *pubourethral ligaments*, the *urethropelvic ligaments*, the *vesicopelvic fascia*, and the *cardinal ligaments*. The pubourethral ligaments anchor the urethra to the undersurface of the

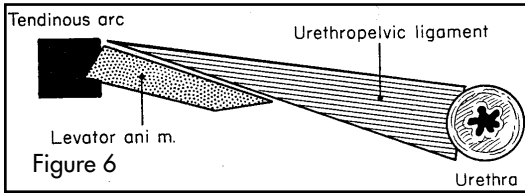


Figure 6
Schematic of Urethropelvic Ligament

pubic bone, providing midurethral support. The urethropelvic ligaments are composed of the leaves of levator fascia (endopelvic and periurethral fascia) that attach the urethra to the

tendinous arc. (Figure 6). This attachment provides support to the urethra at times of increased abdominal pressure. Weakness of the urethropelvic ligaments is present in females with stress urinary incontinence. The vesicopelvic fascia is composed of the leaves of levator fascia at the level of the bladder (endopelvic and perivesical fascia), which anchor the bladder to the tendinous arc and pelvic side walls and provide bladder support. Weakness in vesicopelvic fascia is present in females with cystoceles. The *prerectal* and *pararectal fascia* are anatomically situated between the rectum and bottom wall of the vagina. When these fascias become weakened, a rectocele results. The cardinal ligaments contain the uterine arteries and provide attachment of the uterus to the pelvic side walls. The sacro-uterine ligaments provide attachment of the cervix to the bony sacrum. Weakness or separation of the cardinal and sacro-uterine ligaments gives rise to

uterine prolapse, enterocele, and vaginal vault prolapse.

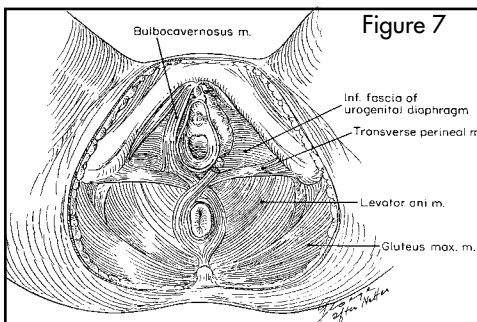
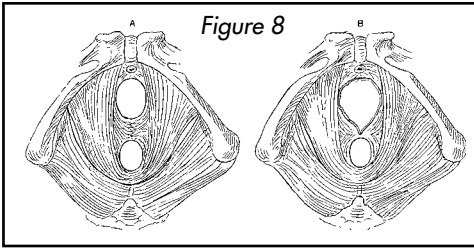


Figure 7
The Female Perineum

The *levator ani muscles* and *urogenital diaphragm* provide support to the rectum and perineum. The *perineum* is the anatomical region between the vagina and anus. The urogenital diaphragm consists of the *bulbocavernosus muscle*, *transverse perineal muscle*,

external anal sphincter, and *central tendon*. (Figure 7).

The vagina can be divided into proximal (deep), middle, and distal (superficial) thirds. The cardinal ligaments support the proximal third,



Perineal View of Normal Levators (left) and Damaged Levators After Childbirth (right)

the tendinous arc attachment the middle third, and the levators and perineal muscles the distal third. When pelvic floor relaxation occurs, the levator muscles and the urogenital diaphragm muscles become flaccid, allowing the openings for the urethra, vagina, and rectum to become

enlarged and the normal angle of the vagina to become altered. (Figure 8). This creates widening of the vaginal opening and shortening of the distance between the vagina and anus, a situation called perineal laxity.

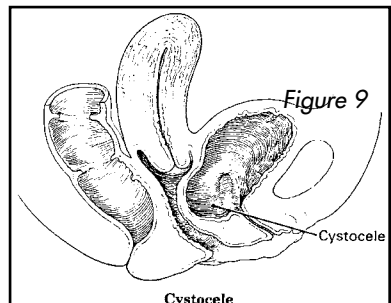
Types of Prolapse

URETHROCELE (urethral hypermobility)
Greek “ourethra”=urethra & “kele”=hernia

The urethra, the tube that conveys urine from the bladder, is about 1½ inches in length and is fused to the distal third of the vagina. Descent of the urethra into the roof of the vagina occurs when its support structures become lax. Detachment of the urethro-pelvic ligaments from the tendinous arc allows such descent. This causes stress urinary incontinence, a spurt-like leakage of urine that can occur with any activity that increases abdominal pressure, typically sneezing, coughing, lifting, laughing, running, dancing, aerobics, etc.

CYSTOCELE (bladder prolapse) (Figure 9)
Greek “kystis”=bladder & “kele”=hernia

Descent of the bladder through a weakness in its supporting tissues gives rise to a cystocele, a.k.a. “dropped bladder,” “prolapsed bladder,” or “bladder hernia.” A *central-defect* cystocele occurs when the bladder falls into the roof of the vagina as a result of a weakness in the perivesical fascia



between the top wall of the vagina and the bladder. A *lateral-defect* cystocele occurs when the attachment of the bladder to the pelvic side wall weakens (the vesicopelvic fascia becomes detached from the tendinous arc). As a cystocele progresses, the amount of descent into the roof of the vagina increases. Cystoceles are graded as follows:

GRADE 1 = mild

GRADE 2 = bladder to vaginal opening (introitus) with strain

GRADE 3 = bladder outside vaginal opening with strain

GRADE 4 = bladder outside vaginal opening at all times

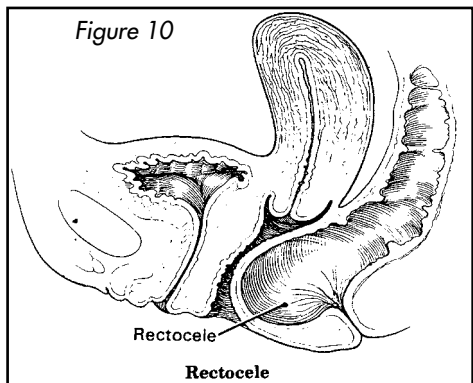
The symptoms of a cystocele are typically one or more of the following:

- a bulge or lump protruding from the vagina
- kinking of the urethra causing obstruction and hence:
 - the need for “manual reduction” (pushing back) of the cystocele in order to urinate
 - obstructive urinary symptoms (a slow, weak stream that stops and starts)
 - irritative urinary symptoms (frequent and urgent urinating)
 - urinary tract infections due to incomplete bladder emptying
- vaginal pain or painful intercourse

RECTOCELE (rectal prolapse) (*Figure 10*)

Greek “rectum”=straight & “kele”=hernia

Ascent of the rectum through a weakness in its supporting tissues gives rise to a rectocele, a.k.a. “dropped rectum,” “prolapsed rectum,” or “rectal hernia.” The rectum protrudes through the floor of the vagina because the levator muscles, prerectal fascia, and pararectal fascia have become lax. As a rectocele progresses, the amount of ascent into the vaginal floor increases. Essentially, a rectocele is an upside-down cystocele.



Rectoceles are graded as follows:

GRADE 1 = mild

GRADE 2 = rectum to vaginal opening with strain

GRADE 3 = rectum outside vaginal opening with strain

GRADE 4 = rectum outside vaginal opening at all times

The symptoms of a rectocele are typically one or more of the following:

- a bulge or lump protruding from the vagina, especially noticeable during bowel movements
- kinking of the normally straight rectum creating a relative obstruction and thus:
 - difficulty with bowel movements
 - the need for “splinting” (holding the rectocele down with your fingers) to empty the bowels
 - fecal soiling
 - incomplete emptying of the rectum
- vaginal pain or painful intercourse

PERINEAL FLOOR RELAXATION

Usually accompanying a rectocele is *perineal muscle laxity*, a condition in which the muscles of the perineum (the anatomical region between the vagina and anus) become lax. Weakness in the levator muscles, the bulbocavernosus muscle, the transverse perineal muscles, and the central tendon occur causing the following anatomical changes:

- a wide and lax vaginal opening
- decreased distance between the vagina and anus
- change in the vaginal angle such that the vagina assumes a more vertical axis as opposed to its normal posterior (downwards) angulation

Women with perineal relaxation who are sexually active may complain of a very loose or gaping vagina, making intercourse less satisfying for themselves and their partners.

ENTEROCELE (small intestinal prolapse) (Figure 11)

Greek “enteron”=intestine & “kele”=hernia

The peritoneum is the thin sac that contains the abdominal organs, including the small intestine. Descent of the peritoneal contents through a weakness in the supporting tissues at the apex of the vagina gives rise to an enterocele, a.k.a.

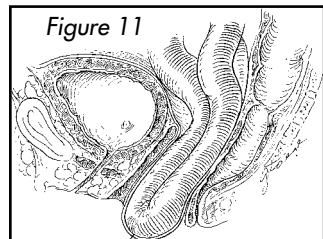


Figure 11

Enterocele

“dropped small intestine,” “small intestine prolapse,” or “small intestine hernia.” Enteroceles are caused by a weakness or separation of the cardinal and sacro-uterine ligaments. As an enterocele progresses, the amount of descent into the vagina increases.

Enteroceles are graded as follows:

GRADE 1 = mild

GRADE 2 = peritoneal sac to vaginal opening with strain

GRADE 3 = peritoneal sac outside vaginal opening with strain

GRADE 4 = peritoneal sac outside vaginal opening at all times

The symptoms of an enterocele are typically one or more of the following:

- a bulge or lump protruding through the vagina
- intestinal cramping due to small intestine trapped within the enterocele
- vaginal pain or painful intercourse

There are several types of enteroceles:

- “pulsion”: from chronically increased abdominal pressure
- “traction”: when other pelvic organs, such as the uterus, bladder or rectum, cause a pull (traction) on the vaginal vault and peritoneum
- “iatrogenic”: following a surgical procedure such as hysterectomy

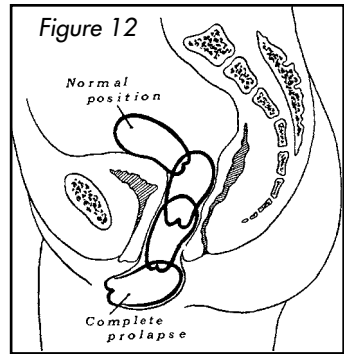
“Simple” enteroceles exist when there is no vaginal vault prolapse; “complex” enteroceles are associated with vaginal vault and uterine prolapse.

VAGINAL VAULT PROLAPSE

The most advanced stage of pelvic relaxation occurs when the support structures of the vagina (cardinal and uterosacral ligaments) are damaged by hysterectomy or other pelvic surgery such that the vaginal vault everts. Vault prolapse, a.k.a. “dropped vaginal vault,” “prolapsed vaginal vault,” or “vaginal vault hernia” is rarely an isolated event, but rather occurs in association with enterocele, cystocele, and uterine prolapse. For illustrative purposes, if the vagina can be thought of as a “sock,” vaginal vault prolapse is a condition in which the sock is turned inside out.

UTERINE PROLAPSE (Figure 12)

Descent of the uterus and cervix because of weakness of their supporting structures (utero-sacral and cardinal ligaments) results in uterine prolapse, a.k.a. “dropped uterus,” “prolapsed uterus,” or “uterine hernia.” Normally, the cervix is located in the deepest third of the vagina. As uterine prolapse progresses, the amount of descent into the vaginal canal will increase. Uterine prolapse is graded as follows:



Uterine Prolapse

- GRADE 1 = descent of the cervix towards the vaginal opening with strain
- GRADE 2 = cervix to vaginal opening with strain
- GRADE 3 = cervix outside vaginal opening with strain
- GRADE 4 = “prolapsed,” complete prolapse in which the cervix and uterus are outside the vaginal opening at all times

The symptoms of uterine prolapse are typically one or more of the following:

- bulge or lump protruding from the vagina
- a sense of “dropping out” and lack of pelvic support
- urinary symptoms: obstructive voiding symptoms, the need to “manually reduce” (push back) the uterus in order to initiate voiding, irritative voiding symptoms, incontinence, urinary tract infections
- kidney obstruction because of descent of bladder and ureters (tubes that drain urine from the kidney to the bladder)
- vaginal pain with sitting and walking
- painful intercourse
- spotting or bloody vaginal discharge

Evaluation of Pelvic Relaxation

Evaluation of pelvic prolapse begins with a thorough history and physical examination. The following questions need to be answered:

- Do you have an introital (vaginal) bulge? What activities promote an increase in the size of the bulge? Do you need to “reduce” the bulge to urinate or defecate? How much is the introital bulge disturbing you? Have you had any prior treatments for the bulge?
- Do you have urinary incontinence, and if so, what type, to what extent, what means are necessary for protection, and how bothersome is it? What activities, if any, promote the incontinence?
- Do you have obstructive voiding symptoms including: hesitancy, decrease in force of the stream, decrease in caliber of the stream, intermittency, the need to strain to void, the feeling that you are not emptying completely, the need to double void?
- Do you have irritative voiding symptoms including: urgency, precipitancy, frequency, nocturia?
- Do you have urinary tract infections?
- Do you have vaginal pain? Are you sexually active, and if so, do you have painful intercourse?
- Do you have a wide and lax vaginal opening that has made sexual relations less satisfying?
- Do you have obstructive rectal symptoms including constipation, incomplete emptying, fecal soiling?
- Do you have flank and back pain when the prolapse occurs?
- What medical problems do you have? Do you have any medical problems that may contribute to pelvic relaxation such as: obesity, chronic coughing, sneezing or wheezing from bronchitis, allergies or asthma, or chronic straining due to constipation? What medications do you take? What allergies do you have to medications? What surgeries have you had, particularly hysterectomy, or prior surgery for pelvic prolapse and incontinence?
- How many pregnancies have you had? How many vaginal deliveries? How large were your babies at birth? Was labor and delivery prolonged or difficult? Was there significant vaginal tearing requiring repair? Do you anticipate having more children?
- If menopausal, at what age did you experience menopause? Are you on replacement female hormone therapy?
- Have you ever fractured your pelvic bones or sustained a significant pelvic injury?
- Is there a tendency for pelvic relaxation and/or incontinence to run in your family, i.e., mother, grandmother, sisters, aunts?

The precise diagnosis of pelvic prolapse is made on the basis of a careful physical exam. The examination must be performed with the patient straining forcefully enough to demonstrate the prolapse at its largest extent. Each region of potential prolapse must be examined independently, i.e., vaginal roof, vaginal apex, vaginal floor.

A thorough pelvic examination involves visual observation, a single blade speculum exam, passage of a small female catheter into the bladder, and a bimanual pelvic exam. Initial inspection will determine the presence of urogenital atrophy (loss of tissue integrity of the genital area, including thinning of the vaginal skin, redness, irritation, etc.), commonly seen after menopause.

A small caliber catheter is passed after voiding for several purposes: to determine the residual urinary volume, to submit a urine culture in the event that the urinalysis suggests a urinary infection, and to determine the change in urethral angulation that occurs with straining. Urethral angulation with straining is a sign of loss of support of the urethra, which gives rise to hypermobility and the symptom of stress urinary incontinence.

In order to observe the top wall of the vagina for the presence of a urethrocele or cystocele, it is important to retract the bottom wall of the vagina down with a speculum. To observe the bottom wall of the vagina for the presence of a rectocele and perineal laxity, the top wall of the vagina must be retracted up with a speculum. To observe the vaginal apex for uterine prolapse and enterocele, both top and bottom walls must be retracted up and down respectively. Once the speculum is placed, the patient is asked to strain vigorously. This speculum examination will determine what specific structure is prolapsed and grade the degree of prolapse.

Finally, a bimanual examination is performed to check for pelvic masses. This is a combined internal and external exam in which the pelvic organs are felt between an internal examining finger within the vagina and an external examining finger on the lower abdomen. The limitation of the physical exam in the lying-down position is that this is NOT the position in which prolapse typically manifests itself. The ideal position to examine prolapse is the standing position, but this obviously is a very difficult and awkward position in which to perform an exam. For this reason a standing x-ray of the contrast-filled bladder at rest and with straining is a useful means of determining the degree and type of bladder prolapse.

Urodynamics is an office procedure helpful in the evaluation of pelvic relaxation. Using sterile technique, a small catheter is placed in the urinary bladder. An additional catheter is placed in the rectum and patch electrodes are placed adjacent to the anal area. The individual catheters will be connected to the computer-assisted urodynamic unit. During the procedure, the pressure in the bladder and the rectum will be monitored as well as the activity of the pelvic floor muscles. When the test begins, fluid at a controlled rate will fill the urinary bladder. You will be asked when you have an initial desire to urinate, when it becomes urgent, and when you feel full. At several times during the procedure you will be asked to strain or cough. Every effort will be made to replicate your symptoms during the course of the study so that the pressures and pelvic floor activity can be measured at that particular time. Once the bladder is filled to capacity, you will be asked to void into the commode at which time the urinary flow rate as well as the pressure within the bladder will be measured. At the end of the urodynamic evaluation, all of the catheters will be removed. The final element of the evaluation is a cystoscopy. During this procedure, the urethra is numbed with anesthetic jelly after which a tiny lighted optical instrument is used to view the urethra, bladder neck, and bladder on a monitor that you will be able to see.

After the urodynamic evaluation has been completed and all the data stored in the computer has been examined. The results of the urodynamic study will be reviewed with you. This study, along with the cystoscopy and cystogram, will provide the necessary quantitative anatomic and functional information to make a precise diagnosis so that management options can be discussed and treatment plans initiated.

Surgical Repair of Pelvic Prolapse

Symptomatic pelvic relaxation can be surgically corrected, with excellent results. The goal of pelvic reconstructive surgery is to restore normal anatomy and function. In addition to improving cosmetic appearance, pelvic reconstruction strives to cure incontinence and voiding dysfunction, and improve bowel and sexual function. The surgical repair of pelvic relaxation is referred to as *pelvic reconstruction*. This may involve one or more of the vaginal compartments. *Anterior* compartment pelvic reconstruction is for repairing a prolapsed bladder; *posterior* compartment pelvic reconstruction is for repairing a prolapsed rectum; *apical* compartment pelvic reconstruction is for repairing prolapsed small intestine. The pelvic reconstruction may or may not be augmented with a piece of netting known as mesh. Mesh repairs are used more commonly when one's native tissues are defective.

Surgical repair of prolapse can often be performed on an outpatient basis. The procedure is performed under either general or regional anesthesia. The entire procedure is performed with your legs in padded stirrups and is done through the vagina. After completion of the surgery, the vagina will be packed with antibiotic gauze for several hours.

Your normal diet and medications can be resumed immediately. You can resume most of your normal activities as soon as possible. In fact, walking and stair climbing are desirable as rapid return to activities facilitates recovery. You may bathe or shower. Any non-strenuous activity is permissible as long as pain is not experienced. Avoid heavy lifting, strenuous exercise, straining at bowel movements, and sexual intercourse. The operative site may hurt more with excess activities. This should be a signal for you to ease up a bit. Vaginal, pubic, and pelvic soreness are normal for several weeks. Vaginal discharge (often bloody), is also typical for several weeks following surgery and it is therefore recommended that you wear a pad.

Prior to being discharged, you will be given typed instructions and a prescription for antibiotics and a pain medication. It is important to complete the prescription for antibiotics to help avoid a urinary tract or pelvic infection.

Surgical Repair of Stress Urinary Incontinence (SUI)

Mid-urethral Sling. Stress urinary incontinence (SUI) is an involuntary spurt-like loss of urine due to a sudden increase in abdominal pressure. It is often provoked by sneezing, coughing, laughing, exercising, changing positions, etc. Underlying contributing factors include childbirth (in particular, traumatic vaginal deliveries of large babies), menopause, hysterectomy, aging, and any condition causing a chronic increase in abdominal pressure such as cough, asthma, and constipation. SUI is usually due to a combination of intrinsic and extrinsic causes. The intrinsic factor, intrinsic *sphincteric deficiency*, is a weakness of the urethral sphincter muscles. The extrinsic factor, *urethral hypermobility*, is an acquired laxity in the tissue support of the urethra that allows urethral descent with increases in abdominal pressure.

The goal of surgical management of SUI is to provide support to the urethra in order to correct the intrinsic and extrinsic deficiencies. There are many variations on surgical techniques to provide sub-urethral support to sure SUI. The surgical treatment of SUI has evolved significantly over the past several decades. The current procedure represents an evolution of surgical technique that has merit because of its effectiveness, durability, relative simplicity, and need for only tiny incisions.

A commonly used surgical procedure for repair of SUI is a *mid-urethral sling*. Its purpose is to cure SUI. It is also performed in conjunction with cystocele (bladder prolapse) repair to prevent the occurrence of SUI that may be unmasked as a result of the cystocele repair. The sling procedure works by providing support and a “backboard” to the urethra such that with “stress” maneuvers such as coughing and sneezing, the urethra can be compressed against the sling to provide continence.

Only a small vaginal incision and a tiny pubic or groin puncture is needed. The stitches used to repair the vagina and will dissolve on their own and do not require removal; the puncture sites are closed with skin glue.

Mid-urethral refers to the placement of the sling beneath the mid-urethra, the tubular channel that leads from the bladder to the urinary opening. The sling placed underneath the urethra recreates the “backboard effect”.

Sling refers to the “hammock” that provides urethral support and that

allows compression of the urethra with stress maneuvers.

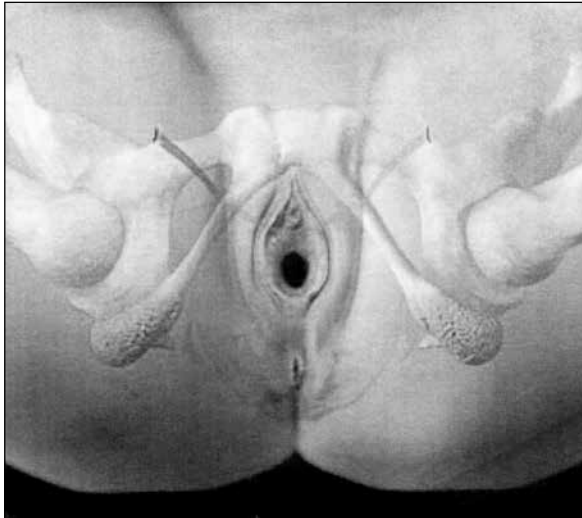
Benefits and Potential Risks of the Sling Procedure

Benefits:

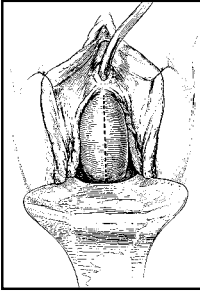
- 90% cure of stress urinary incontinence
- 65% of patients with pre-existing urgency incontinence that accompanies the stress urinary incontinence will have resolution of the urgency incontinence

Potential Adverse Effects:

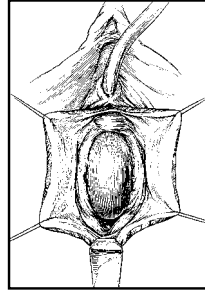
- Failure of the procedure to cure the SUI in 10%
- New onset of urgency incontinence in 5-10%. Urgency incontinence is a sudden urge to urinate with the inability to make it to the bathroom on time. If this occurs, it can be treated with a bladder relaxant medication.
- Prolonged time before resumption of spontaneous voiding in 2.5%
- Inability to urinate in less than 1% requiring self-catherization or takedown/revision of the sling
- Injury to the urethra, bladder, bowel, or vascular structures: extremely rare.
- Protrusion of sling material: extremely rare



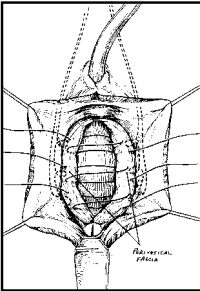
Surgical Repair of Cystocele (Classic Repair)



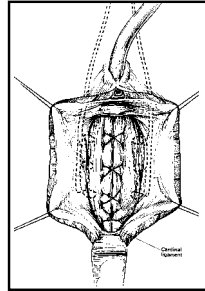
Incision in anterior vaginal wall



Exposure of hardy perivesical fascia

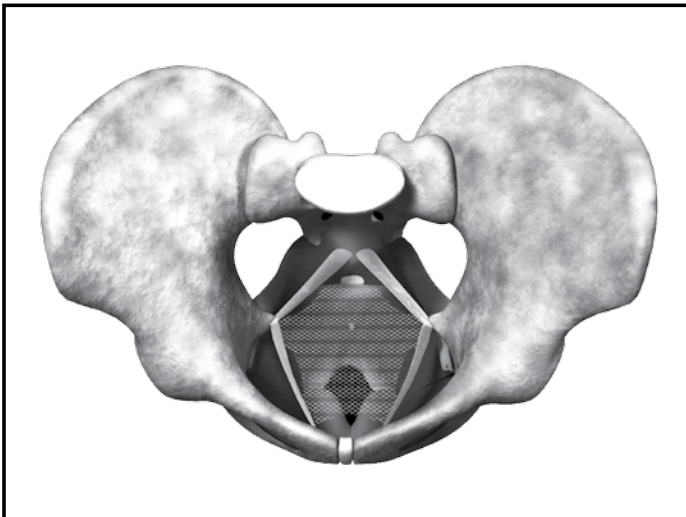


Perivesical fascia sewn together in midline to obliterate cystocele

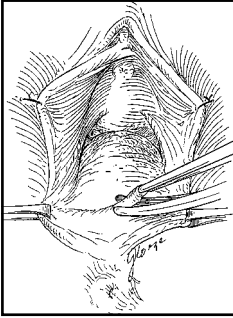


Completion of cystocele repair

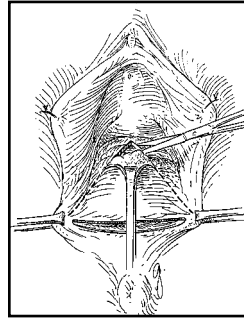
Mesh-Augmented Cystocele Repair



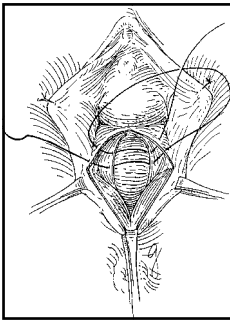
Surgical Repair of Rectocele



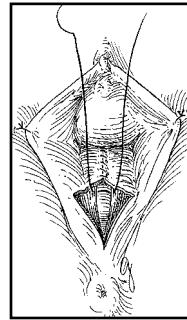
Wedge of perineal skin removed



Rectocele dissected off posterior vaginal wall

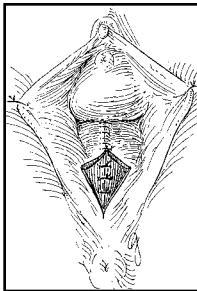


Perirectal & pararectal fascia sewn together in midline

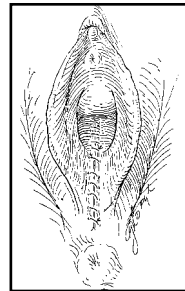


Levator muscle sewn together

Perineal Repair

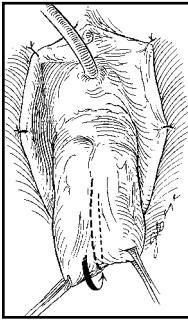


Perineal muscles repaired

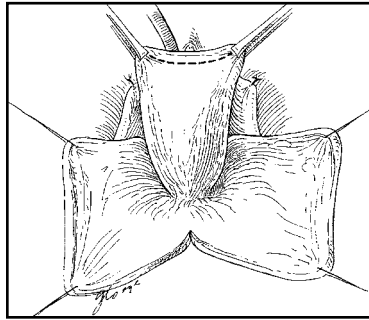


Completed rectocele and perineal repair

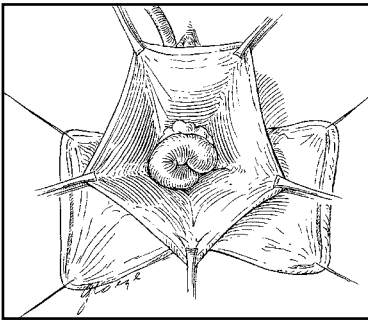
Surgical Repair of Enterocele and Vault Prolapse



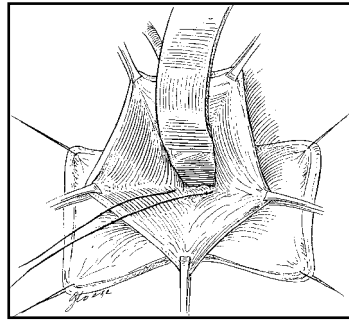
Vaginal incision over enterocele



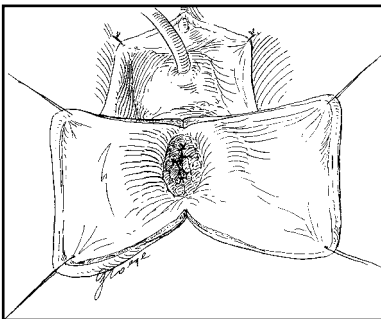
Enterocele sac is opened



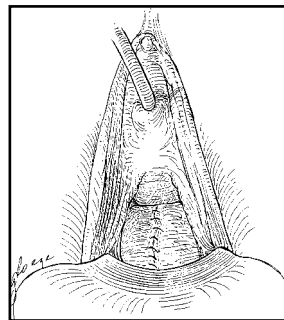
Contents of enterocele are exposed



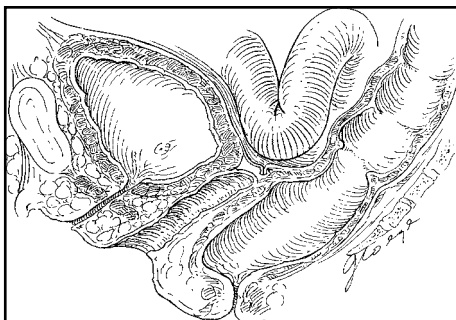
Intestines retracted in order to repair enterocele



Neck of enterocele is now closed



Completion of enterocele repair



*At completion of enterocele repair,
intestines are back in their proper position*

Robotic-Assisted Laparoscopic Sacrocolpopexy

When vaginal vault prolapse is advanced and the vagina literally turns inside out and pooches out of the body, it will often require an abdominal procedure to reattach the innermost portion of the vagina so that it is properly moored and cannot prolapse. This is often indicated in a woman with severe vault prolapse who wishes to remain sexually active. Using a laparoscopic approach with the aid of the robot, a small piece of mesh is attached to the innermost portion of the vagina on one end and the sacrum on the other hand, securing the vagina so that it cannot prolapse and maintaining the length and axis of the vagina.

Surgical Repair of Uterine Prolapse

If the uterine prolapse is low to moderate grade, consideration for uterine suspension can be made, a procedure in which the uterus is secured to the pelvis in order to prevent its descent. Essentially, a piece of surgical mesh is sutured to the uterine cervix, and the other end of the mesh is attached to one of the hardy pelvic ligaments. This results in the re-establishment of uterine support and a return of the uterus to its normal anatomical position. However, if the uterine prolapse is high grade, hysterectomy is the option of choice. Hysterectomy is the surgical removal of the uterus, a procedure that can often be performed vaginally by your gynecologist. If high grade uterine prolapse coexists with bladder and urethral prolapse, the gynecologist and urologist will collaborate to repair all aspects of the prolapse.

About the Author

Dr. Andrew Siegel earned a medical degree from the Chicago Medical School, Chicago, Illinois, where he was elected to the Alpha Omega Alpha Honor Medical Society.

He completed a two-year residency in general surgery at the North Shore University Hospital, Manhasset, New York, an affiliate of Cornell University School of Medicine. Dr. Siegel then went on to undertake residency training in urology at the University of Pennsylvania School of Medicine, Philadelphia, Pennsylvania. Dr. Siegel completed a fellowship in voiding dysfunction, urodynamics, reconstructive and female urology at the UCLA School of Medicine, Los Angeles, California, under the direction of Dr. Shlomo Raz, prior to joining Bergen Urological Associates.

Dr. Siegel is a diplomate of the American Board of Urology and the National Board of Medical Examiners and is board certified in both Urology and Female Pelvic Medicine & Reconstruction Surgery. He is a member of the American Urological Association, the American Uro-Gynecological Society, the International Continence Society, the Society for Urodynamics, Female Pelvic Medicine and Urogenital Reconstruction, and the Sexual Medical Society of North America.

Dr. Siegel has authored chapters in urology textbooks including *Current Operative Urology* and *Interstitial Cystitis*, and has published articles in numerous professional journals including *Urology*, *Journal of Urology*, *Urology Clinics of North America*, *Postgraduate Medicine*, *Neuro-Urology and Urodynamics*, and *International Urogynecology Journal*. He has presented papers at professional meetings for many medical societies including the Philadelphia Urological Society, the American Academy of Pediatrics, the American Urological Association, and the American College of Surgeons.

He is a urological surgeon at Hackensack University Medical Center and a Clinical Assistant Professor of Urology at Rutgers New Jersey Medical School.

Dr. Siegel has authored the books: *Finding Your Own Fountain of Youth – The Essential Guide to Maximizing Health, Wellness, Fitness & Longevity*; *Promiscuous Eating: Understanding and Ending Our Self-Destructive Relationship With Food*; and *Male Pelvic Fitness: Optimizing Sexual and Urinary Health*.

